

College of Emergency Medicine of South Africa Policy Document**Emergency Ultrasound in South Africa****Part 1 – Credentialing for Emergency Ultrasound**

A provisional policy statement by the Emergency Ultrasound Subcommittee of the College of Emergency
Medicine of South Africa

The authors of this document consist of the following members of the subcommittee:

Mike Wells BSc(Med).Hons, MBBCh, Dip PEC(SA)¹

Stevan Bruijns MBChB, Dip PEC(SA), MPhil²

1. Division of Emergency Medicine, University of the Witwatersrand
2. Joint division of Emergency Medicine, Universities of Stellenbosch and Cape Town

Corresponding Author:

Dr M Wells

+27 11 724 2113/ +27 82 491 0369

mike@casualty.co.za

PO Box 773, Glenvista, Johannesburg, South Africa 2058

Introduction

This policy document has been adapted and modified, in parts, with permission, from the policy documents of the American College of Emergency Physicians (ACEP)¹, the Australasian College for Emergency Medicine (ACEM)² and the College of Emergency Medicine in the United Kingdom.³ As these have been modified, this document does not necessarily reflect the views of these organisations.

Proficiency in basic Emergency Ultrasound (EUS) is an essential skill for emergency physicians and clinicians involved in the emergency care of adults or children.⁴ It has been shown to augment the clinician's ability to assess and manage critically ill or injured patients and to increase the clinician's confidence in the initial emergency department (ED) management.⁵⁻⁸ EUS is not only an invaluable adjunct in the resuscitative management of unstable patients, but also has a role to play in many aspects of the ED management of more routine cases. EUS may be defined as a limited, goal-directed examination used to answer specific clinical questions (e.g. "Is there free fluid in the abdomen?" but not "Is there any intra-abdominal injury?"). These examinations are not comprehensive and do not replace formal ultrasound examinations performed by radiologists.

The College of Emergency Medicine of South Africa (CEM(SA)) supports the development of EUS in South Africa, and recommends that equipment and expertise be available in the ED to ensure that appropriate emergency ultrasound examinations can be rapidly performed, 24-hours per day. Emergency physicians performing EUS should possess appropriate training and practical experience to perform and interpret basic emergency ultrasound examinations.

This document details the credentialing procedure for emergency physicians or other clinicians who wish to perform EUS in the ED on trauma patients (EFAST), patients with suspected abdominal aortic aneurysms (AAA), patients with suspected deep vein thrombosis (DVT) of the lower limbs, and as an adjunct in the placement of central venous catheters (CVC).

Basic Emergency Ultrasound

The CEM(SA) recommends that emergency physicians be proficient in:

1. EFAST (Extended Focused Assessment by Sonography in Trauma). This is an ultrasound examination used to detect the presence of haemoperitoneum, haemothorax, haemopericardium and pneumothorax via at least 6 ultrasound views:
 - a. Morrison's pouch (hepato-renal angle), the right hemidiaphragm and the right postero-inferior pleural space.
 - b. The spleno-renal angle, the left hemidiaphragm and the left postero-inferior pleural space.
 - c. Subcostal (subxiphoid) or parasternal views of the heart and pericardium.
 - d. Transverse and longitudinal views of the pelvis to assess for fluid in the recto-vesical pouch (male) or recto-uterine pouch (female).
 - e. Bilateral pleural views obtained in the second intercostal space, mid-clavicular line (and elsewhere if needed) to assess for pneumothorax.
2. AAA assessment. This is a scan of the aorta with transverse and longitudinal views, from the diaphragm to the bifurcation. The study should include measurements of the maximum transverse antero-posterior diameter of the aorta.
3. Focused Emergency Echocardiography in Resuscitation (FEER). This is a limited echocardiogram used in the setting of non-shockable cardiac arrest rhythms (PEA and asystole). The heart is interrogated during a rhythm check for wall motion and the treatable causes of PEA (hypovolaemia, pulmonary embolism, cardiac tamponade and pneumothorax). The subxiphoid view is primarily used, followed by the parasternal long and short axis views and the apical four chamber view.
4. DVT assessment. This is a two-point compression examination of the veins of the lower limbs. The deep veins of the lower limb are evaluated for compressibility at the level of the popliteal vein and the common femoral vein.
5. CVC insertion. The use of real-time ultrasound as an adjunct to internal jugular vein or femoral vein catheterisation, using either the in-plane or out-of-plane approach, has been shown to increase the success rate and decrease the complication rate when compared with traditional landmark techniques. There is not enough evidence to support the use of EUS with the insertion of subclavian CVCs.

Once accredited in basic EUS, emergency physicians can further develop their repertoire of ultrasound skills. This may include basic airway, thoracic, biliary, renal, obstetric, testicular, musculoskeletal and soft-tissue ultrasound, and ultrasound-guided procedures (including nerve blocks).

The credentialing process

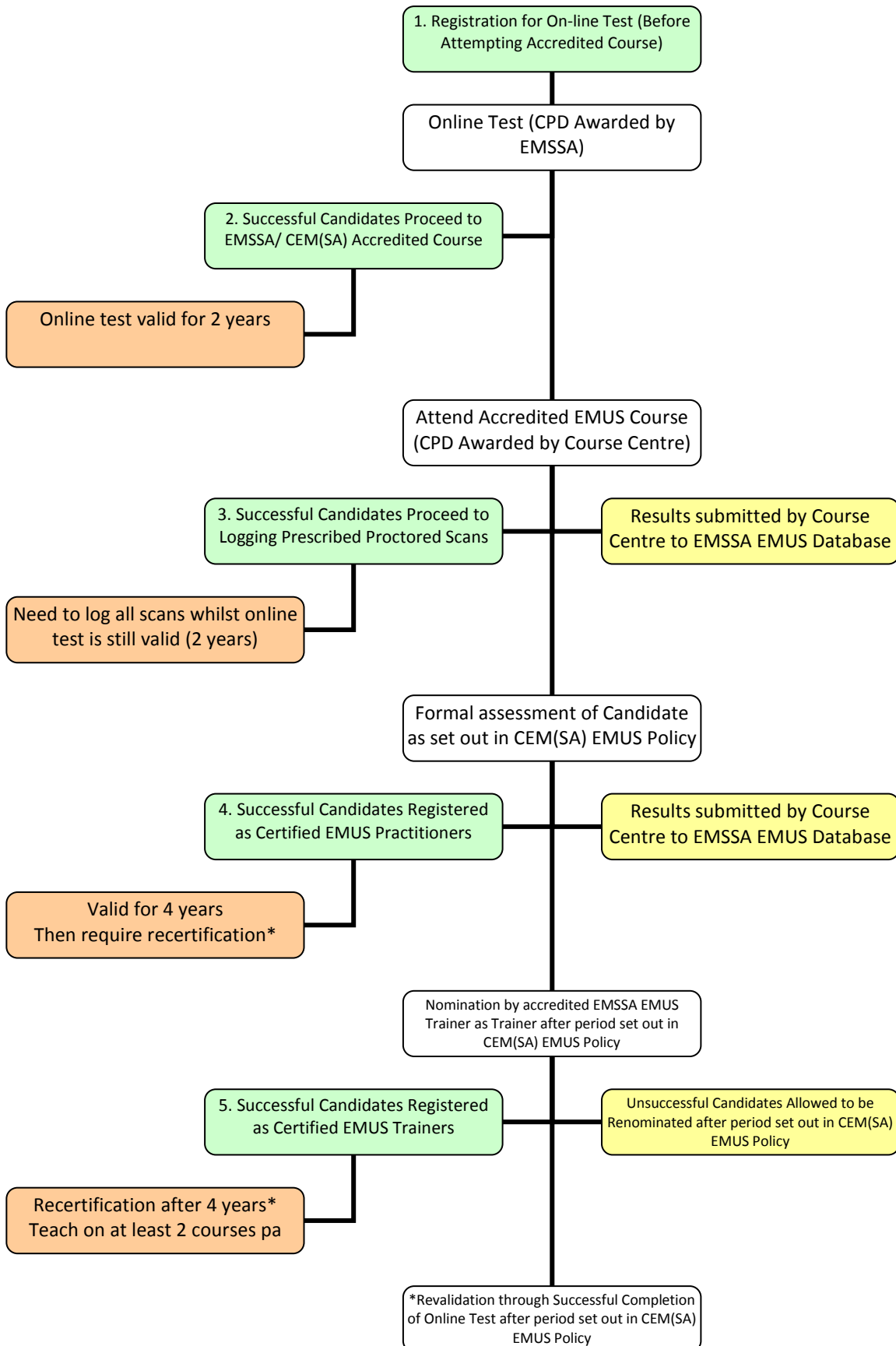
This process requires the candidate to attend an accredited training course, to perform and log a specified number of emergency ultrasound examinations in the ED, and then pass an examination ratified by the CEM(SA).

Clinicians who have been using EUS as described in this document, but have not been through the credentialing process can apply in writing to the CEM(SA) to confirm their competence if they have a letter from a specialist radiologist or a specialist emergency physician with extensive ultrasound experience confirming their competence. CEM(SA) may at the discretion of the members of the subcommittee decide to forego the first two requirements subjecting successful applicants to the final formal assessment only.

In order to maintain their credentialing, emergency physicians must meet ongoing maintenance requirements. Registrars in emergency medicine will be expected to demonstrate their knowledge and proficiency in EUS during the FCEM part 1, FCEM part 2 or both; candidates may not attempt the FCEM part 2 until they have been credentialed in EUS as described in this document.

The proposed process of EMUS training, certification and revalidation is set out in Figure 1. Initial candidate contact will be through online registration for the online test allowing inclusion in the database (access through www.emssa.org.za). As candidates progress successfully through the pathway, results will be fed back to the database by the course centre allowing the different registration levels.

Figure 1 The proposed process of EMUS training, certification and revalidation



Registration levels will be (see figure 1 above):

1. Registration, pre-test
2. Registration, online test completed
3. Registration, course completed
4. Registration and certification for independent practice
5. Registration, trainer
6. Registration and certification for independent practice: grandparent clause
7. Deregistered, lapse of retesting

Except in the event of the grandparent clause used in order to register for independent practice, candidates must progress step-wise from registration level one to four in order to register and certify for independent practice. Should a candidate be nominated by an existing trainer, the candidate will progress to registration level five. The process of registration by means of the grandparent clause is discussed in the proposed policy document.

EUS training courses

In order to run training courses, course programs must be accredited by the Emergency Ultrasound Subcommittee. Course conveners can apply in writing to the CEM(SA). Applications should include a detailed course program and a short resume of trainers. Accreditation of course centres will be reviewed annually.

Training should include instruction relevant to both the performance and interpretation of focused emergency ultrasound examinations. The course content must include:

- Basic physics applicable to ultrasound scanning.
- The operation (knobology) of ultrasound machines.
- Generating an image, optimising visualisation of structures and identifying common artefacts.
- The normal and abnormal anatomy relevant to the scan.

The course should contain both theoretical instruction (ideally in an interactive manner) and practical, hands-on instruction and practice on human models (with the exception of the vascular access techniques). At the

end of the session candidates should be formally assessed to determine that they have acquired an understanding of the principles and practice of emergency ultrasound including: machine operation, artefacts, image optimising and orientation, patient positioning and respiratory manoeuvres. Candidates must also show that they are able to recognise significant abnormalities as presented to them as hard copies or digital images of scans.

EUS training days

Training days can be used to assist trainee sonographers in logging the scans required in order to progress to the final formal assessment. Accredited sonographers may use training days to update their CPD portfolio. Trainee sonographers may also complete their final assessment on such a training day. Training days will employ patients known to have AAA or who use peritoneal dialysis to stand in respectively for AAA and peritoneal free fluid (EFAST) assessments. It is important however that approximately half of the individuals being assessed have normal anatomy. In order to run training days, course centres must be accredited by the Emergency Ultrasound Subcommittee. Course conveners can apply in writing to the CEM(SA). Applications should include a detailed program and a short resume of all trainers. Accreditation of course centres will be reviewed annually.

Trainee sonographers are encouraged to sit in on cardiac echo or ultrasound examinations. Even though this would not count toward the logged assessments it would help familiarise prospective sonographers with the relevant anatomy.

Logged ultrasound examinations

Patients should be informed that the EUS examination is being performed for credentialing purposes. Results may only be used for clinical decision making if the EUS was performed by an accredited sonographer or observed by a trainer. Verbal consent should be obtained and so documented in the notes. All EUS examinations must be logged on the log-sheet provided by the CEM(SA) (see Appendix 1). The findings and interpretation of the scan must be indicated in addition to relevant follow-up data as to whether the scan was accurate. Hard copies or digital recordings of relevant images should be attached to the log-sheet.

A minimum of 65 scans should be logged for submission for credentialing purposes:

- EFAST – 20 scans.
- AAA assessment – 15 scans.
- FEER assessment – 15 scans
- DVT assessment – 10 scans.
- CVC access – insertion of 5 internal jugular or femoral vein lines assisted by ultrasound.

At least 50% of these scans should be clinically indicated, and at least 10 scans should have abnormal findings (5 must demonstrate intraperitoneal, pleural or pericardial fluid and 5 abdominal scans should demonstrate an aneurysm). At least half of these scans must be proctored (supervised) examinations under the direct supervision of a proctor approved by the CEM(SA). A proctor may be a specialist radiologist or an emergency physician experienced in EUS who has been approved by the CEM(SA) to supervise these examinations. The CEM(SA) recommends that training organisations conduct regular “training days” with volunteer patient models (selected for a range of pathologies), to enable candidates to log the required proctored EUS examinations.

The credentialing examination (final formal assessment)

The CEM(SA) will offer bi-annual examinations in EUS according to a published schedule. Candidates will be able to register for the examination once they have completed their logged and proctored scans. The examination will consist of two elements: an objective structured clinical examination (OSCE), which will test the candidate's theoretical and practical knowledge of the subject; and a practical and oral examination where the candidate will be observed and examined while conducting an ultrasound examination. The candidate will be required to display the ability to create adequate ultrasound images of all the appropriate anatomical structures, and must be able to identify any relevant artefacts or pathology present during real-time scanning. The candidate must be able to recognise an inadequate scan and must demonstrate an understanding of the indications and limitations of EUS examination for the condition in question.

Once the examination requirements are satisfied the candidate will be credentialed for basic emergency ultrasound and may then document the results of their scans into the clinical record and incorporate the results into clinical decisions.



Maintenance of credentials

To maintain currency in EUS, the emergency physician must perform a minimum of 50 scans per year (EFAST 25, AAA 10, DVT 10, CVC 5) and must undertake at least 3 hours of ultrasound training (or alternatively obtain 3 CEUs in ultrasound) per year.

Documentation of ED ultrasounds

Each diagnostic or procedural ultrasound scan performed in the ED should be recorded in the clinical records, and should be noted as an EFAST or “limited ED ultrasound” to avoid confusion with formal radiologist-performed ultrasounds. Ideally a proforma report form should be used. The notes should record whether the findings were normal, abnormal or indeterminate. Inadequate studies should be clearly identified so that the results are not used for clinical decision-making.

References

1. American College of Emergency Physicians. Emergency Ultrasound imaging criteria compendium. *Ann Emerg Med.* 2006;48(4):487-510.
2. Australasian College for Emergency Medicine. Credentialling for ED ultrasonography: Trauma examination and suspected AAA. *Emerg Med.* 2003;15(1):110-111.
3. College of Medicine UK. CEM - Specialised Skills Training - Ultrasound. Accessed July 2008. Available from: <http://www.collemergencymed.ac.uk/>.
4. Reardon R, Heegaard B, Plummer D, Clinton J, Cook T, Tayal V. Ultrasound is a necessary skill for emergency physicians. *Academic Emergency Medicine.* 2006;13(3):334-336.
5. Sloth E, Larsen KM, Schmidt MB, Jensen MB. Focused application of ultrasound in critical care medicine. *Crit Care Med.* 2008;36(2):653-654.
6. Levy JA, Noble VE. Bedside ultrasound in pediatric emergency medicine. *Pediatrics.* 2008;121(5):e1404-1412.
7. Kirkpatrick AW, Blaivas M, Sustic A, Chun R, Beaulieu Y, Breitzkreutz R. Focused application of ultrasound in critical care medicine. *Crit Care Med.* 2008;36(2):654-655.
8. Kirkpatrick AW, Ball CG, D'Amours SK, Zygun D. Acute resuscitation of the unstable adult trauma patient: bedside diagnosis and therapy. *Can J Surg.* 2008;51(1):57-69.

Appendix 1: CEM(SA) Emergency Ultrasound Log Sheet

Name of patient		File nr.	
Location		Date	
Name of sonographer		Sign	

<input type="checkbox"/> Chest			
Is cardiac motion present?	Yes <input type="checkbox"/>	No <input type="checkbox"/>	Inadequate <input type="checkbox"/>
Is pericardial effusion present?	Yes <input type="checkbox"/>	No <input type="checkbox"/>	Inadequate <input type="checkbox"/>
Is pneumothorax present?	Yes <input type="checkbox"/>	No <input type="checkbox"/>	Inadequate <input type="checkbox"/>
Is dilated RV present?	Yes <input type="checkbox"/>	No <input type="checkbox"/>	Inadequate <input type="checkbox"/>
Is flat IVC (< 5mm) present?	Yes <input type="checkbox"/>	No <input type="checkbox"/>	Inadequate <input type="checkbox"/>
<input type="checkbox"/> Abdomen			
Is free fluid present?	Yes <input type="checkbox"/>	No <input type="checkbox"/>	Inadequate <input type="checkbox"/>
If yes, where?	<ul style="list-style-type: none"> • Hepatorenal recess <input type="checkbox"/> • Pelvic recess <input type="checkbox"/> • Splenorenal recess <input type="checkbox"/> 		
<input type="checkbox"/> Aorta			
Is the aorta enlarged ($\geq 3\text{cm}$)?	Yes <input type="checkbox"/>	No <input type="checkbox"/>	Inadequate <input type="checkbox"/>
If so, what was the largest measured diameter	cm		
<input type="checkbox"/> Deep Venous Thrombosis			
Is thrombus present	Yes <input type="checkbox"/>	No <input type="checkbox"/>	Inadequate <input type="checkbox"/>
If yes, where:	<ul style="list-style-type: none"> • Femoral vein <input type="checkbox"/> (Left <input type="checkbox"/> Right <input type="checkbox"/>) • Popliteal vein <input type="checkbox"/> (Left <input type="checkbox"/> Right <input type="checkbox"/>) 		
<input type="checkbox"/> Central venous cannulation			
Is the target visible?	Yes <input type="checkbox"/>	No <input type="checkbox"/>	Inadequate <input type="checkbox"/>
Successful cannulation?	Yes <input type="checkbox"/>	No <input type="checkbox"/>	Inadequate <input type="checkbox"/>
Area accessed:	<ul style="list-style-type: none"> • Internal jugular <input type="checkbox"/> • Femoral <input type="checkbox"/> 		
To validate this log, please attach a copy of the ultrasound images to this sheet			

Post hoc evaluation. Results confirmed through:		
<ul style="list-style-type: none"> • Ultrasound by accredited practitioner <input type="checkbox"/> • Surgical means <input type="checkbox"/> • CT/ MRI <input type="checkbox"/> 		
Other (specify):		
Images review (to be completed by accredited trainer)		
Image quality:	<ul style="list-style-type: none"> • Adequate <input type="checkbox"/> • Inadequate <input type="checkbox"/> 	
Interpretation:	<ul style="list-style-type: none"> • Correct <input type="checkbox"/> • Incorrect <input type="checkbox"/> 	
Name:	Sign:	Date:



Notes: